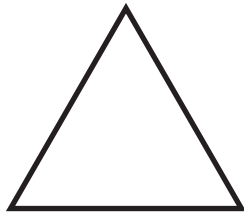


MARROW



SPINAL CORD

BRAIN